


**PRESENTING CLINICAL SIGNS**

**DATE** History: Presented for chronic respiratory issues/restrictive breathing pattern. Abnormal BNP. Currently receiving prednisolone 0.42 mg/kg/day. Radiographs on 2/15 showed mild cardiomegaly, equivocal bronchial markings. Intolerant of lateral recumbency during echo.

2/17/23

**ECHOCARDIOGRAPHIC FINDINGS**

**PERFORMED BY:** An abbreviated 2D, M-mode, and color Doppler study was performed.

Dr. Eileen Jenkins

**INTERPRETED BY** There is mild left atrial dilation. The mitral valve appears normal, though mild mitral regurgitation is present. Left ventricular wall thickness is normal. Left ventricular dimensions are normal. Left ventricular systolic function is hyperdynamic. The aorta and aortic valve are normal. Right atrial and right ventricular dimensions are normal. The tricuspid valve leaflets are mildly thickened, and there is Doppler evidence of tricuspid regurgitation present. TR velocity is consistent with the presence of very mild pulmonary hypertension (PG 33.4 mmHg). The pulmonary artery and pulmonic valve appear normal, though trace pulmonic insufficiency is present. No shunting lesions are visualized. No pericardial effusion or cardiac masses are seen.

Keith Blass, DVM, MS, DACVIM (Cardiology)

**PATIENT** IVSd - 4.9 mm  
LVPWd - 4.8 mm  
LVIDd - 14.8 mm  
LVIDs - 8.8 mm  
FS - 40.5%

Yankee Dime Davis

**SPECIES ELECTROCARDIOGRAPHIC FINDINGS**

Feline A single lead ECG is submitted for review.

HR: 214  
Rhythm: Sinus with a VPCs

**BREED** The underlying rhythm is sinus in origin. All sinus complex amplitudes and intervals are within normal limits. A single VPC is present. No atrial ectopy or conduction blocks are seen.

**DSH**

**RADIOGRAPHIC FINDINGS**

**SEX** Three-view thoracic radiographs are submitted for review.

**FS** There is mild generalized enlargement of the cardiac silhouette. The pulmonary vessels are within normal limits. There are faint pulmonary bronchial markings. The pleural space is within normal limits. The trachea is normal. The remainder of the thorax is unremarkable.

**ASSESSMENT/RECOMMENDATIONS**

**AGE** 13 y

**WEIGHT** Yankee's echocardiogram demonstrates mild dilation of her left atrium, with differentials for this finding including a restrictive cardiomyopathy (RCM), atrial myopathy, or cardiac thyrotoxicosis. Given the presence of mild left atrial dilation, it's possible that Yankee's respiratory clinical signs could be, at least in part, cardiogenic in origin, however, no evidence of cardiogenic pulmonary edema or pleural effusion is appreciated in her radiographs, therefore, this cannot be confirmed. No other reason for Yankee's respiratory symptoms is appreciated in her radiographs.

6 kg

**HOSPITAL NAME** Yankee's ECG demonstrates the presence of a single VPC. Mild ventricular arrhythmias are well-tolerated in cats, though careful monitoring for progression is recommended.

Huntsville Vet. Spec. & Emergency

A T4 level is recommended.

**REFERRING VET** Given the presence of mild left atrial dilation, a trial with furosemide (6.25 mg BID) may be

Dr. Jenkins



warranted. I also recommend starting Yankee on clopidogrel (18.75 mg SID). If Yankee has been receiving prednisolone for a long period of time and the medication appears to be helping, it's likely that it can be continued.

DATE

2/17/23

A renal/electrolyte profile is recommended in 1-2 weeks if furosemide is to be continued long-term. A recheck echocardiogram and ECG are recommended in ~6 months.

PERFORMED BY:

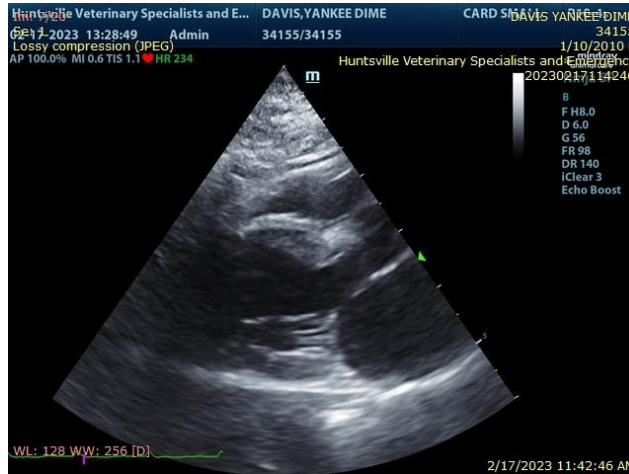
Dr. Eileen Jenkins

INTERPRETED BY

Keith Blass, DVM,  
MS, DACVIM  
(Cardiology)

PATIENT

Yankee Dime Davis



SPECIES

Feline

The information and recommendations provided are based on the images presented by the referring veterinarian. No evaluation can be communicated regarding pathology that was not visible in the image/video clips provided.

BREED

Thank you for this referral. If the clinical or image interpretation does not parallel your findings or if I can be of any further assistance please contact me.

DSH

SEX

Keith Blass, DVM, MS, DACVIM (Cardiology)  
KeithBlass@gmail.com  
631-804-5754

FS

AGE

13 y

WEIGHT

6 kg

HOSPITAL NAME

Huntsville Vet. Spec.  
& Emergency

REFERRING VET

Dr. Jenkins